

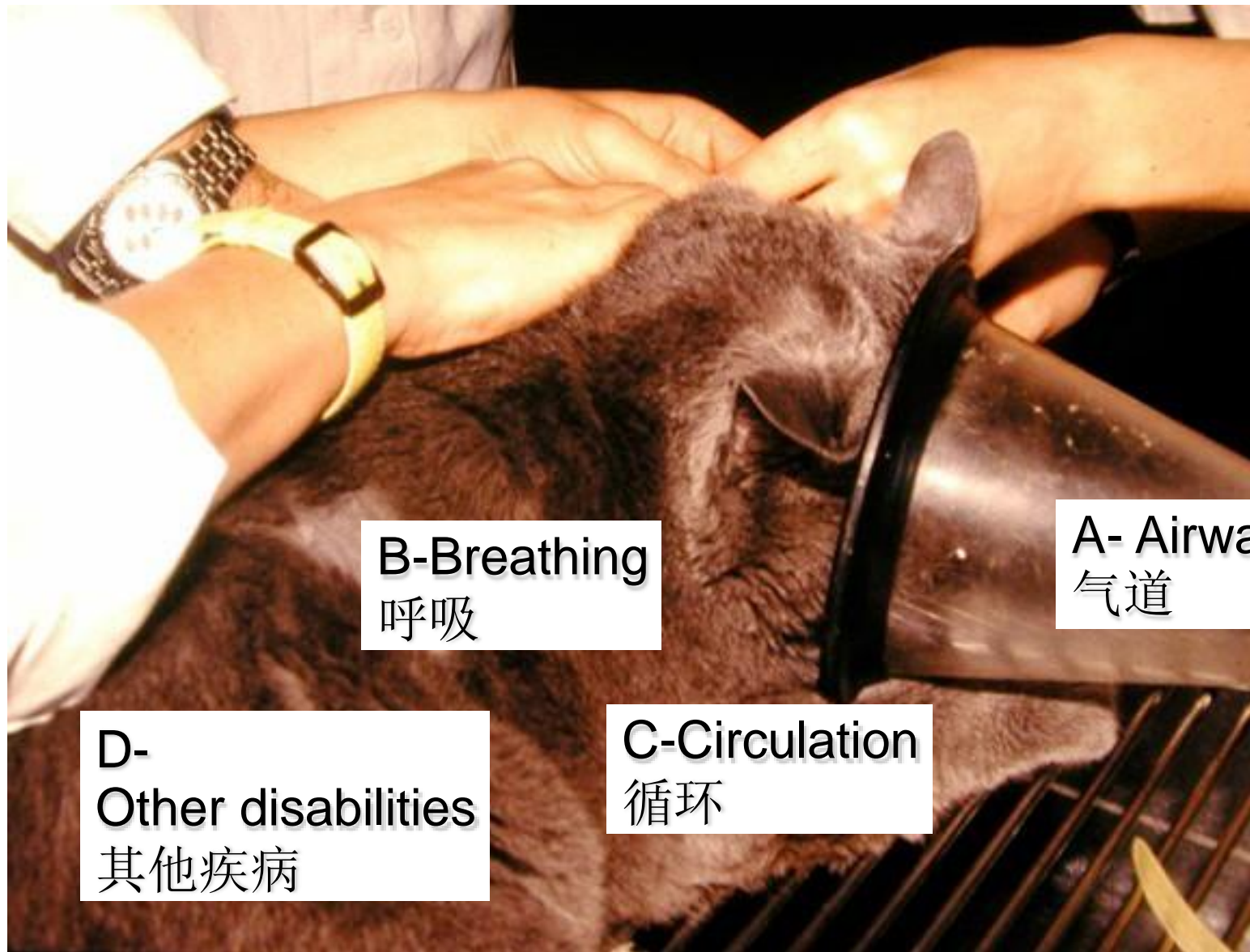


Trauma in Cats- From the Emergency room

Eva Schnabl, Dipl. ECVS
University of Veterinary Medicine
Veterinärplatz 1
1210 Vienna/Austria/Europe
eva.schnabl@vetmeduni.ac.at



Traumatology 创伤学



B-Breathing
呼吸

A- Airway
气道

D-
Other disabilities
其他疾病

C-Circulation
循环

A- Airway 气道

Control Airways!

控制气道

Nasopharyngeal Area ok?

鼻咽部是否正常

Larynx and Trachea ok?

喉部和气管是否正常

Lung ok?

肺部正常

Thoracocentesis!

胸腔穿刺

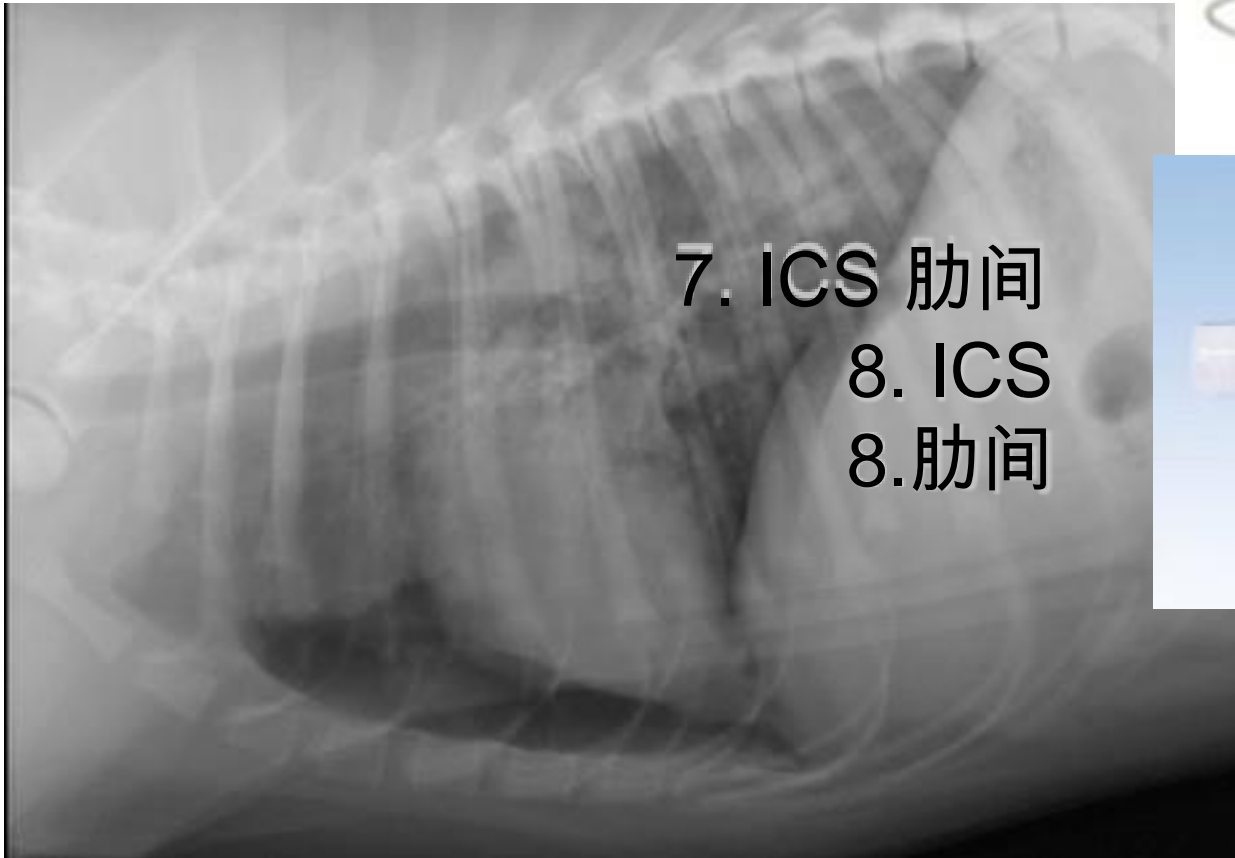
No radiologic examination of the patient before

Stabilisation!

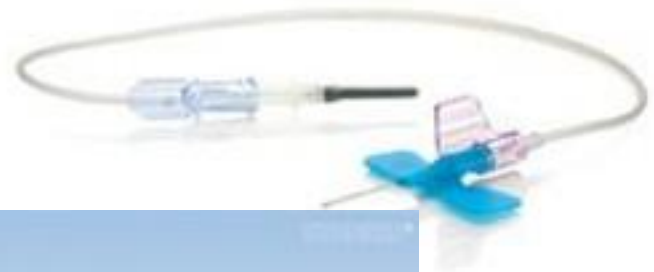

B- Breathing 呼吸

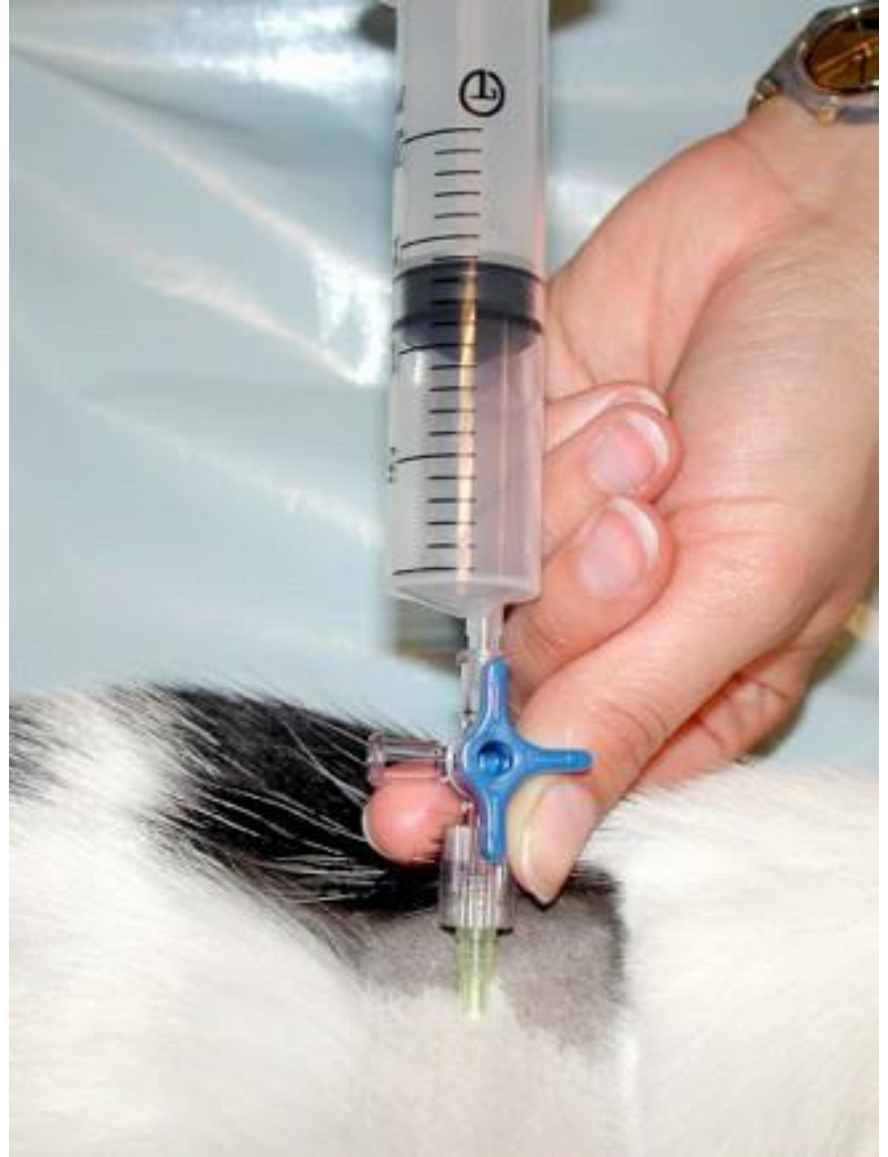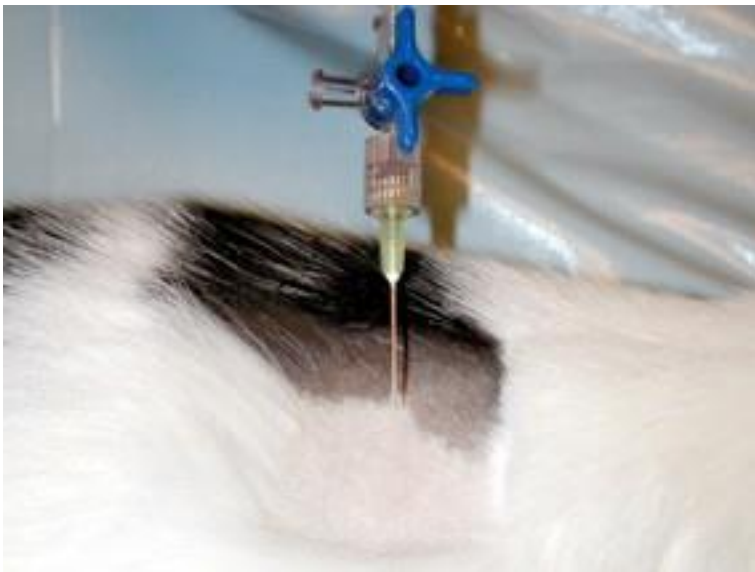Pneumothorax- Thoracocentesis 气胸——胸腔穿刺术



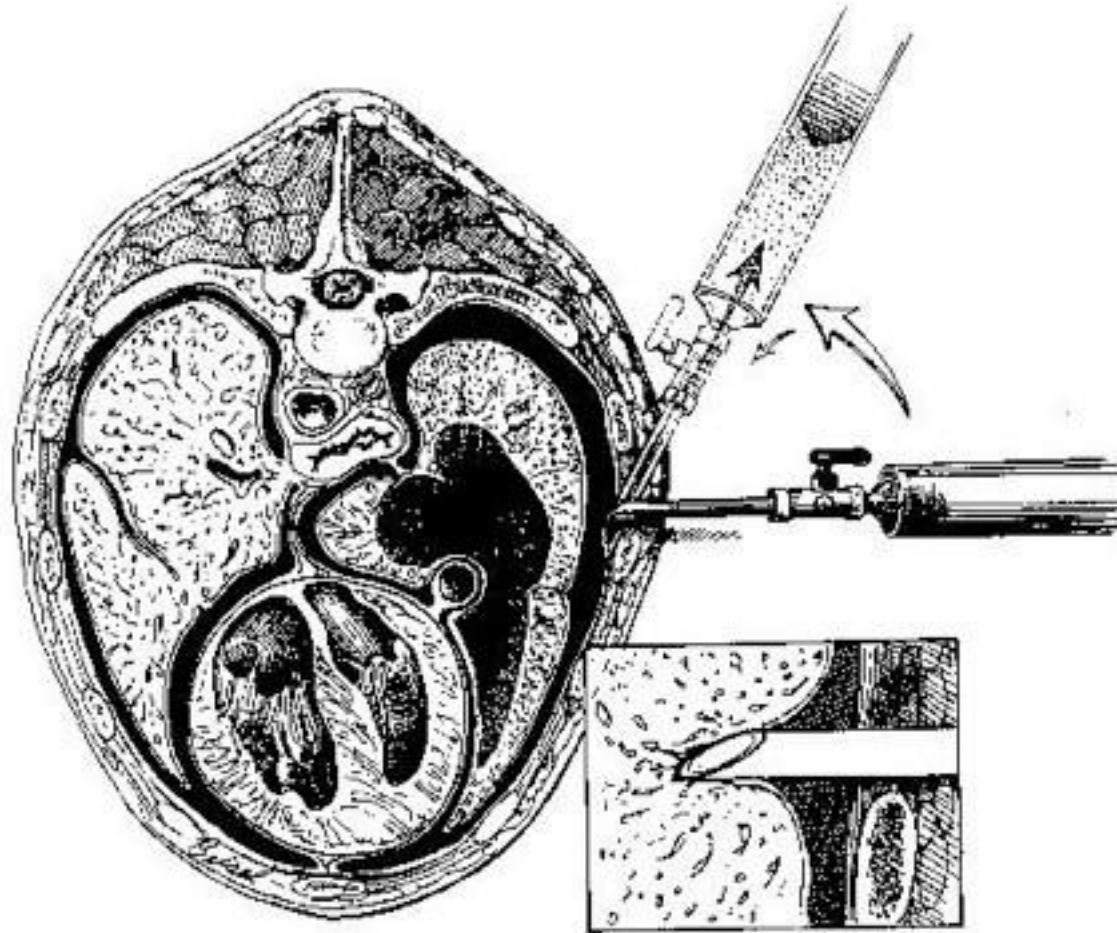
7. ICS 肋间
8. ICS
8.肋间



A- Airway 气道



A- Airway 气道



以上内容仅为本文档的试下载部分，为可阅读页数的一半内容。如要下载或阅读全文，请访问：<https://d.book118.com/388132023016006036>